Reclaiming Clinical Confidence: The Diastolic Murmur

The diastolic murmur is always a signifier of cardiac pathology and is never benign. In this article, Dr. Fenske discusses how the recognition of certain clinical clues and cardiac assessment of the carotid pulse will help clinicians discover the diastolic murmur and its underlying complications.

T. K. Fenske, MD, FRCPC, FACC, FCCP

The physical examination is under attack. We choose technology, not only to take care of the menial tasks of data storage and retrieval, but also to investigate our patient's complaints and even to attempt to think for us. If Sir William Osler's day was the "golden age" of patient-focused clinical enlightenment, our's is the computer age of information overload, moving us at high speed away from the bedside. Distracted by our machines that go bing, we fail to realize that the most important tool that we can bring to the patient's bedside is ourselves, with concern and thoughtfulness. Clinical acumen is not in competition with medical technology. The two can and need to work hand in hand. Our clinical diagnostic skills benefit from ongoing updates and refinement, easily accomplished, for example, by correlating echocardiography results with bedside findings. Medical imaging is most powerful within an accurate clinical context, where specific questions like "how severe is the aortic insufficiency (AI)" are posed, rather than vaguely asking, "is any structural heart disease present?" Otherwise, we relegate our high technology to rambling and expensive diagnostic "fishing trips." If we neglect our role as clinicians, facile with the art of physical examination, our proud medical profession becomes reduced to a technical vocation and the patient gets lost in the shuffle of lab results and imaging reports.

The presence of a diastolic murmur always signifies cardiac pathology. Unlike systolic flow murmurs that can occur in healthy hearts, diastolic murmurs are never benign. Unfortunately, diastolic murmurs can be

Allan's heart problems

Allan, a 52-year-old oil field worker, presented to the ED with visceral chest pain of two-hour duration associated with diaphoresis and dyspnea.

His physical exam was initially thought to be unremarkable, overshadowed by the impressive ST depression in his anterior precordial ECG leads and disregarded when his troponin came back elevated. His symptoms responded to anticoagulation and nitrates and he was admitted to the coronary care unit as a routine non-STEMI for further observation and risk stratification.

On bedside rounds the next morning his nurse reported that although he was pain-free, he had developed a fever in the night and requested to give him some acetaminophen. "Probably atelectasis" the senior mumbled as we gathered to see the man.

His heart rate was regular at 102 bpm with a BP of 156/72 mmHg. He felt warm and had a brisk carotid upstroke with collapsing pulses. Palpation of his precordium revealed a hyperdynamic normally placed apical impulse, palpable medial to the midclavicular line with only one finger.

Auscultation revealed soft first and second heart sounds with a left-sided third heart sound. As well, at the base of the heart there is a grade 2/6 early-peaking crescendo-decrescendo systolic murmur that radiated to both clavicles and extended along the left sternal border, unchanged with either Valsalva maneuver or handgrip. The remainder of his cardiovascular exam was unremarkable with the patient in the supine position.

What is causing the murmur and might it affect his management? Turn to page 45 to find out...

Copyright© Not for Sale or Commercial Distribution
Unauthorised use prohibited. Authorised users can download, display, view and print a single copy for personal use

Table 1
Differential diagnosis of the diastolic murmur

Common causes	Less common causes
Aortic insufficiency	Pulmonary insufficiency
Mitral stenosis	Tricuspid stenosis
	Ventricular septal defect (VSD) with high shunt flow
	Left atrial myxoma
	Cor triatriatum

difficult to appreciate and can be easily missed. Table 1 lists some important causes of diastolic murmurs, of which the more common AI and mitral stenosis will be covered in this review. Although the prevalence of rheumatic mitral stenosis in the western world has markedly declined in the post World War II era, the disease continues to thrive in developing countries and represents a major global health burden.

The challenge of the diastolic murmur

Detecting a diastolic murmur poses a number of challenges, even for the practiced clinician. Firstly, pathologies that produce diastolic murmurs are less common than those that produce systolic murmurs. As a result, we have fewer examples to draw from and add to our memory repertoire. Secondly, the frequency range of diastolic murmurs is different from the more familiar systolic murmurs. Diastolic events including the murmurs of AI and mitral stenosis, as well as the third and fourth extra heart sounds, occur at the extremes of our normal hearing range (Figure 1).[1] The diastolic murmur of AI is a high frequency sound, similar to and often camouflaged by the patient's breath sounds. By contrast, the diastolic rumble of mitral stenosis is a low frequency sound and can be compared to a far-off train or distant thunder. In fact, the frequency of the mitral stenosis murmur can be so low that it is perhaps better thought of as an absence of silence. As a result, diastolic murmurs don't slap you across the face with their presence. One has to be tuned in and focussed to appreciate such murmurs, blocking out everything else. True to the words of Arthur Conan Doyle's Sherlock Holmes who explained, "elementary my dear Watson, I found it because I was looking for it."

This review has two parts. The first portion will highlight the clinical clues that identify patients more likely to have diastolic pathology, namely assessing the carotid pulse, palpating for collapsing pulses, and examining the apical impulse. The second portion will outline the techniques that can help uncover the otherwise veiled diastolic murmur, including optimal positioning of the patient and the stethoscope and specific dynamic auscultation maneuvers.

Compiling clinical clues

Diastolic murmurs must be sought out. But one need not hunt for a diastolic murmur on every single patient examined. We need to be selective and time efficient in our examination efforts. It is far more valuable to thoughtfully tailor the physical exam to answer the clinical questions at hand, rather than just going through the motions of a complete exam. We must be able to recognize the clinical findings that hint at the presence of diastolic pathologies. Aware of these specific clinical clues, the clinician can then go after the diastolic murmur to clinch the diagnosis far more effectively.

Dr. Fenske is an Associate Clinical Professor, University of Alberta and Principal Teacher for Undergraduate Medical Education, Royal Alexandra Hospital, Edmonton, Alberta.

Clues from the vital signs

The first clues to the presence of diastolic pathology lie in heart rate and BP determination. Legend has it that Sir William Osler diagnosed a patient with mitral stenosis from the foot of the bed by palpating the patient's big toe. Lucky guess? It would certainly seem so, but considering that rheumatic valve pathology was the leading cause of heart disease in his day, and that atrial fibrillation (AF), also known as pulsus mitrale, was commonly found in those with significant mitral stenosis, it was more likely an educated guess. I would not try this on ward rounds since the finding of an irregular pulse today is not specific for mitral stenosis. Nonetheless, the presence of AF in patients with valvular heart disease is a useful indicator of increasing severity.

The pulse pressure, measured as the difference between systolic and diastolic readings, can offer a valuable clue to the presence of significant AI. A widened pulse pressure, defined as > 50% of the systolic pressure, occurs with chronic significant AI. The systolic pressure is elevated due to the increased stroke volume and the diastolic pressure reduced because of the baroreceptor-induced peripheral vasodilation and diastolic run-off. The pulse pressure increases as the pulse wave moves further from the heart, being more pronounced in the legs than the arms. The ankle-brachial index can offer a measure of AI severity, known as Hill's sign (a palpatory ankle systolic BP which is 20 mmHg greater than a simultaneously measured brachial palpatory systolic BP), although some investigators feel that its' value has been overstated.[2] Generally the more marked the pulse pressure, the more severe the chronic AI with some caveats. The systolic accentuation in AI becomes more pronounced with aging as the vasculature loses its elastic recoil capacity. As well, coexistent hypertension can maintain a normal or even high diastolic pressure despite significant AI.

Clues from the carotid pulse

As a central pulse, inches from the heart, the carotid upstroke and volume can provide critical information regarding cardiac hemodynamics and should be assessed during every cardiovascular examination. Ejection of blood from the

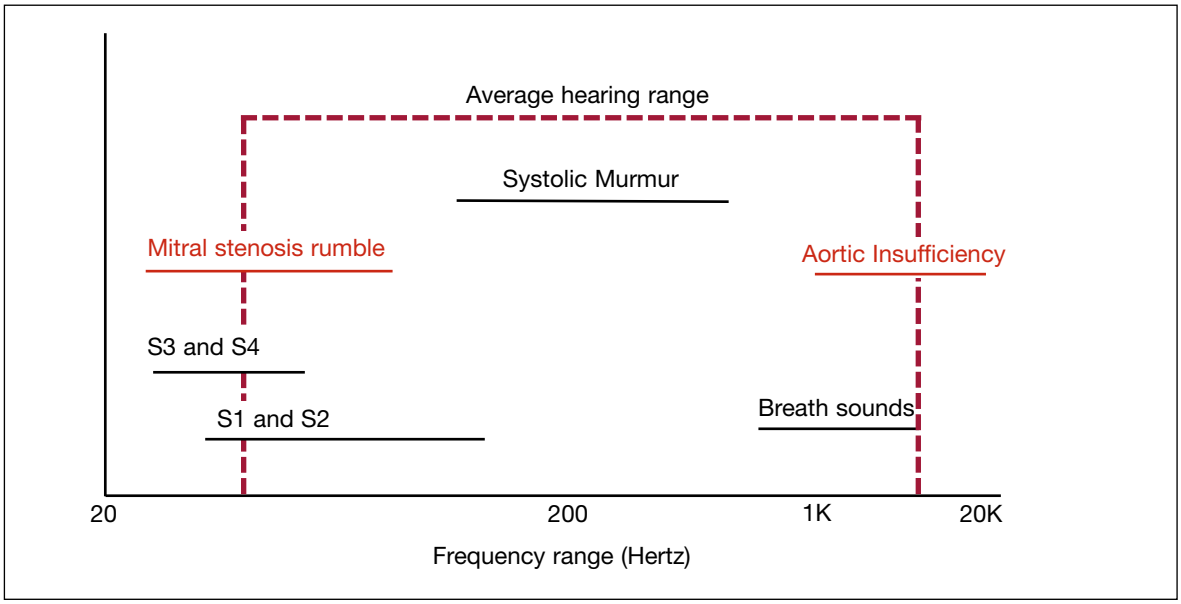

Figure 1. Auscultation frequency ranges.

left ventricle into the aorta causes systolic expansion of the carotid arteries. This is represented as the initial slope of the ejection phase of the cardiac cycle (Figure 2). The best technique to discern this slope is to apply firm pressure with your left thumb over the patient's right carotid pulse. Locate the pulse just medial to the sternocleidomastoid muscle, at the level of the thyroid cartilage (Figure 3). A normal carotid upstroke has a tapping quality and can be referenced to the examiner's own carotid pulse. Increased force of myocardial contraction causes the upstroke to be brisk, perceived by the examining thumb as "flicking" on the thumb, rather than "tapping." A brisk carotid upstroke can occur with any hyperdynamic condition including:

- sepsis,
- anemia,
- pregnancy and
- hyperthyroidism.

Cardiac conditions that can produce a brisk carotid upstroke include:

- significant aortic valve regurgitation (AR),
- mitral insufficiency,
- hypertrophic obstructive cardiomyopathy (HOCM) and
- ventricular septal defect.

Each of these cardiac conditions can be clinically differentiated on the basis of their respective systolic murmurs.[3] When combined with aortic stenosis, the large stroke volume of AI causes the carotid artery to vibrate. This phenomenon, termed a carotid shudder or bisferiens pulse, is powerful evidence for AI, rendering auscultation almost redundant.

The amount of arterial expansion is referred to as the carotid volume and represents the arterial pulse pressure. In significant chronic AI the pulse pressure widens. An incompetent aortic valve forces the left ventricle to eject not only the left atrial blood coming at it, but also the fraction of stroke volume that has been regurgitated. This now giant stroke volume causes the elevation in the systolic BP and produces a high volume carotid pulsation. When visible to inspection, this exaggerated pulsation in the neck is referred to as a Corrigan's pulse, resembling a bullfrog in extreme cases. Together with a brisk carotid upstroke, an increased carotid volume should instruct the clinician to think AI.

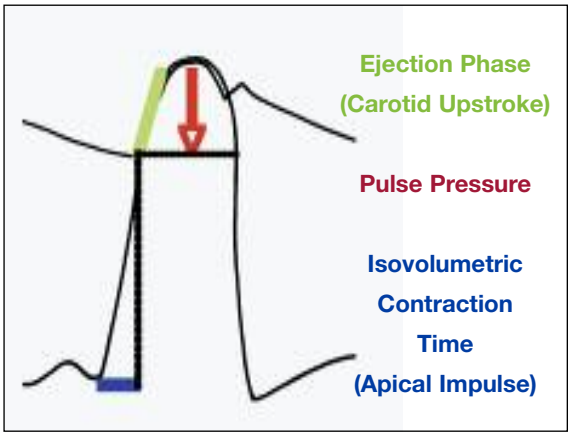

Figure 2. Hemodynamics of the cardiac cycle.

Assessing for a collapsing pulse

A collapsing pulse refers to the slapping sensation when holding the tissue of the forearm of a patient with significant AI. The large stroke volume occurring in AI stretches the left ventricle at end-diastole and increases the inotropic ejection force by the Starling effect, propelling the increased volume at high velocity into the aorta. An obscure child's toy in Victorian England secured itself a position in the history books of medicine when clinicians of the time compared it to the pulse of AI. The toy was called a water hammer and consisted of a glass tube filled partly with water or mercury under a vacuum seal. The liquid produced a slapping impact when the glass tube was shaken or turned over. This colourful analogy has been perpetuated with the term "water hammer pulse" to denote the collapsing pulse of AI. To check for the presence of a collapsing pulse, grasp the patient's forearm firmly with both hands in a clamshell squeeze,

holding the arm first in the horizontal position, and then raising it passively to the vertical (Figure 4). With severe aortic valve incompetence the slapping impulse can be immediately felt with the arm horizontal. In less severe cases, the slapping impulse may only become apparent when the arm is lifted vertically. Vertical positioning of the arm increases the diastolic run-off by applying gravity and exaggerates the collapsing pulse sensation. Other signs representing the same physiology include Quincke's nailbed pulsation and the digital throb, but are less specific and far less valuable.

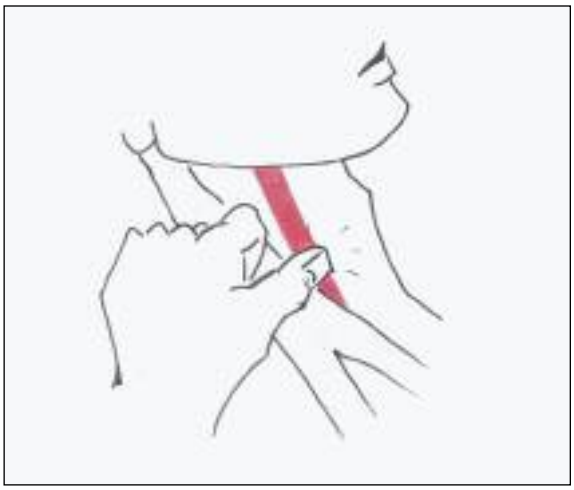

Figure 3. Carotid artery palpation.

Clues form the apical impulse

The apical impulse is defined as the most inferolateral palpable precordial impulse and represents the isovolumetric contraction time (IVCT) of the cardiac cycle (Figure 2). During this portion of the cardiac cycle, the left ventricle contains its full blood volume, the ventricular walls thicken and the heart rotates in a counter clockwise rotation (as seen from below, looking upwards). This allows the apex of the heart to come into transient contact with the chest wall, before the aortic and pulmonary valves open. To best palpate the apical impulse, apply firm pressure over the inframammary region of the precordium using the volar aspect of the mid-phalanges of the right hand, with the patient lying supine and to the left of the examiner. Sometimes palpating the apex with the patient in the left lateral decubitus position helps to make it more apparent, since the heart moves closer to the chest wall. The key features of the apical impulse include its location, size and duration.

The location and size of the apical impulse are both clinical indicators of heart size. The normal apical impulse should measure within 10 cm of the midsternal line (MSL), or medial to the mid-clavicular line. The "10 cm rule" seems to hold regardless of patient size, since the larger the patient, the more difficult it is to localize the most lateral aspect of the impulse. The size of the apical impulse should be no larger than the width of two fingertips and palpable in only a single intercostal space. If three fingertips can palpate the apex or if it is palpable in two separate intercostal spaces, then the impulse is diffuse and the heart is likely enlarged. If left untreated, severe AI can lead to massive left ventricular enlargement, referred to as *cor bovinium* or cow heart. A diffuse and deviated apical impulse gives a clue to volume overload and fits with severe chronic AI.

In mitral stenosis, the left ventricle is protected by the stenotic mitral valve, maintaining a normal apical size and location. However, the fibrocalcified rheumatic mitral valve can close with such force that it may be palpable at the apex when the patient is in the left lateral decubitus position. A palpable S1 feels like a transient flicking sensation superimposed onto the pushing of the apical impulse and should pique ones' interest in assessing the intensity of the first heart sound by auscultation.

Clues from auscultation

The most notable clue for the presence of mitral stenosis is a loud first heart sound. Unlike hyperdynamic states that can intensify both heart sounds, a rheumatic fibrocalcified valve closes with a bang, causing only the first heart sound to be accentuated. A first heart sound is considered loud if it is more intense than S2 at the base of the heart. When this is the case, listen for the opening snap of mitral stenosis occurring in early diastole and heard best with the diaphragm over the apex. This high-pitched extra heard sound has a cadence like saying the word Kentucky (*i.e.*, Listen for *Bang duSnap*). Brisk AV conduction can also produce a loud first heart sound (confirmed by measuring a short PR interval on EKG), but is differentiated from mitral stenosis by the absence of the cadence. As mitral stenosis progresses in severity, pulmonary hypertension can develop, referred to as the second stenosis. In such cases, the pulmonary (P2) component of the second heart sound becomes louder than the aortic (A2) component. This is best appreciated by comparing the intensity of the second heart sound between the left (P2) and right (A2) basal parasternal regions.

Focussing on the intensity of the heart sounds and on the presence of extra heart sounds may not point the clinician towards the presence of AI, but can provide useful information regarding the severity of the leak and even the etiology. The first heart sound may be softened by the impingement of the AI jet onto the anterior mitral valve, preventing it from fully opening and, in severe cases, causing it to prematurely close. With volume overload of the left ventricle as occurs with severe AI, a third heart sound may be evident, heard best with the light application of the bell over the apex with the patient in the left lateral decubitus position. When the AI is related to a bicuspid aortic valve, an early

Allan's case cont'd...

Although only a systolic murmur was audible when Allan was lying supine, things changed when he was asked to sit upright with legs dangling over the edge of the bed and instructed to make a fist with both hands and hold his breath after exhaling.

When firm pressure was applied on the stethoscope diaphragm over the lower left sternal border, he was found to have a grade 2/6 diastolic decrescendo murmur, consistent with aortic insufficiency. The systolic murmur was secondary to the increased flow across the aortic valve.

Echocardiography confirmed the valve incompetency and the reason; he had an endocardial vegetation attached to the aortic valve, a piece of which had embolized down his otherwise pristine left anterior descending artery vessel, causing his acute coronary syndrome. An antibiotic regimen and not an angioplasty/stent was the effective treatment for this infarct presentation.

This case illustrates the importance of a careful cardiovascular physical examination, even for the "routine" cases.

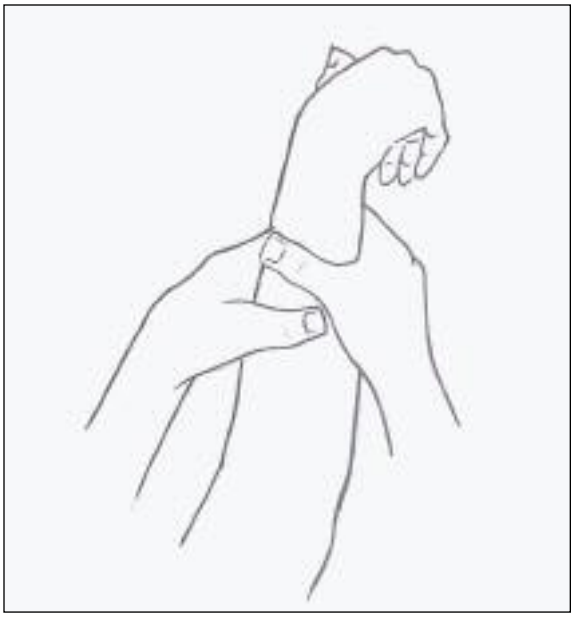

Figure 4. Collapsing pulse.

systolic high-pitched ejection click may be audible at the base of the heart and along the left sternal border.

Both AI and mitral stenosis can be associated with systolic murmurs. In AI, a crescendo-decrescendo systolic ejection murmur at the base of the heart may be due to a combined stenotic and incompetent aortic valve, or merely represent increased blood flow across the aortic valve. As well, it is common to have mitral insufficiency combined with mitral stenosis in rheumatic heart disease. In both cases, the systolic murmur is easier to hear but is often of less pathologic significance than the presence of the enigmatic diastolic murmur.

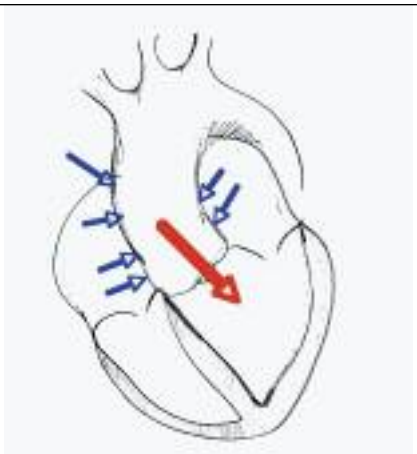

Handgrip increases peripheral vascular resistance which amplifies aortic insufficiency murmur

Figure 5. Handgrip maneuver.

Amplifying the diastolic murmur

If the clues point to diastolic pathology, the challenge remains to bring out the murmur. To best hear a diastolic murmur one has to do some prep work:

- positioning the patient,
- adjusting the stethoscope and
- applying dynamic maneuvers.

The boy scouts' adage of being prepared goes a long way in exposing a hidden diastolic murmur.

Patient positioning

AI is best heard when the patient is sitting upright with legs dangling over the bedside or when standing. Either position exaggerates the murmur of AI by both increasing peripheral vascular resistance (which increases the amount of AI) and reducing preload return to the heart (increasing the amount of AI relative to the total stroke volume). Having the patient lean forward brings the heart closer to the stethoscope as does having the patient exhale. To avoid losing the murmur in amongst breath sounds that share a similar frequency range, ask the patient to exhale and hold their breath.

To bring out the diastolic rumble of mitral stenosis, have the patient assume the left lateral decubitus position. In this position, the heart rotates in the thorax and comes into close contact with the inframammary rib cage, improving pick-up of mitral events at the apex.

Stethoscope positioning

To amplify the high frequency murmur of AI, use the diaphragm of the stethoscope over the lower left sternal border. Press firmly enough to leave an imprint on the skin to damp out low frequencies and unmask the high frequencies.

By contrast, since mitral stenosis is a low frequency murmur, use the bell of the stethoscope. The bell works by making use of the loose underlying skin of the patient as the membrane to collect sound from the chest wall and transmit it to the stethoscope tubing.[4] If undo pressure is applied to the bell, the underlying skin becomes taught which tends to damp out the desirable low frequencies. Holding the stethoscope by the tubing rather than with the bell, with just enough pressure to prevent room-noise leak, will give best results. As well, locating the apex is important since the diastolic rumble of mitral stenosis is often only heard directly over the palpable apical impulse, disappearing even if only centimetres away.

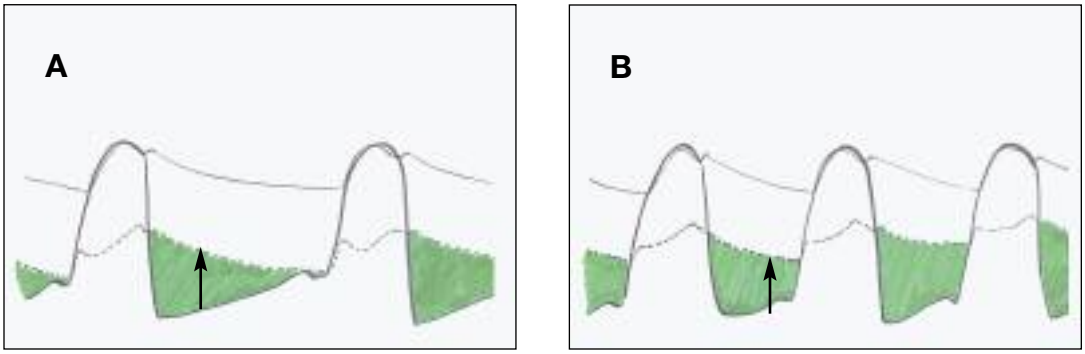

- Slower heart rate
- Longer diastolic filling period
- Lower transvalvular gradient

- Faster heart rate
- Shorter diastolic filling period
- Higher transvalvular gradient

Figure 6. Diastolic filling period.

Dynamic auscultation

The isometric handgrip can help amplify both the diastolic murmur of AI and mitral stenosis. Asking the patient to clench both fists causes localized ischemia in the hands, increasing peripheral vascular resistance and cardiac afterload, with resultant increase in heart rate. The higher afterload on the heart tends to increase the amount of back flow across an incompetent aortic valve (Figure 5).

The higher heart rate shortens the diastolic filling period and intensifies the mitral stenosis rumble. With less time to fill the left ventricle, left atrial pressure rises with concomitant rises in transmitral gradients. The gradient across the rheumatic mitral valve is responsible for the audible rumble (Figure 6). If handgrip isn't enough to raise the heart rate, have the patient perform five assisted sit-ups on the examination table. For best results, be ready with your stethoscope and apply the bell to the apex immediately after the patient has completed the sit-ups and reassumed the left lateral decubitus position.

Conclusion

If we recognize certain clinical clues, we will be more likely to bring out the diastolic murmur and uncover important cardiac pathology. Incorporating time-honoured cardiac assessment of the carotid pulse, collapsing pulses and the apical impulse, with optimal patient positioning and use of dynamic auscultation, can greatly assist the clinician in being more confident in determining the presence of a patient's diastolic murmur. This allows for a more discriminate use of investigations such as echocardiography, which can then be used to both further define the patient's valvular pathology and serve as a means of feedback for the clinical assessment.

References
1. Selig, MB: Stethoscopic and Phonoaudio Devices: Historical and Future Perspectives. Am Heart J 1993;126(1):262-8.
2. Kutryk M, Fitchett D: Hill's Sign in Aortic Regurgitation: Enhanced Pressure Wave Transmission or Artefact? Can J Cardiol 1997; 13(3):237-40.
3. Perspectives in Cardiology 2003; June/July.
4. Constant J: *Bedside Cardiology*. Third Edition. Little, Brown and Company, Boston/Toronto, 1985, pp. 153-5.